



LAPORAN KASUS—CASE REPORT

Radiological modalities in the Colli Sinisitra tumor

Anak Agung Ayu Niti Wedayani^{1*}, Novia Andansari Putri Restuningdyah¹, Rabsanjani¹

¹Fakultas Kedokteran, Universitas Mataram, Indonesia

*Korespondensi:
nwedayani@gmail.com

Abstract

We reported that a 66-year-old male patient was suspected of having colli meningioma tumor. Although 90% of all patients with colitis can be diagnosed on conventional clinical and radiological basis, a biopsy is mandatory for histological confirmation and treatment planning.

Kata Kunci: Tumor Coli, MRI

INTRODUCTION

Head and neck tumors are the seventh most common cancer in incidence, and eighth in terms of mortality. The neck is an exposed part of the body and therefore swelling in this area is easily recognized by the patient or detected during routine examinations. In addition, congenital cervical lesions, inflammation, and malignancy are relatively common.

The incidence in developing countries compared to developed countries is even higher. Patients with head and neck tumors follow an intensive and expensive treatment regime that most often consists of concurrent chemoradiotherapy. In 2003 it was estimated that head and neck cancer would comprise 2%-3% of all cancers in the United States and for 1%-2% of all cancer deaths. This total includes 19,400 cases of oral cavity cancer, 9500 cases of laryngeal cancer, and 8300 cases of pharyngeal cancer. Most patients with head and neck cancer (regional nodal neck cancer have metastatic disease at diagnosis in 43% and metastases in 10%. Head and neck cancer includes a broad group of common tumors that are often aggressive in their biologic behavior. In addition, patients with head and neck cancers and neck often develop into secondary primary tumors. 1-3

Surgery is not standardized in most patients with locally advanced tumors, but is often performed in other groups of patients. In addition, many patients with locally advanced tumors show an inadequate response to treatment.

Conventional anatomic magnetic resonance imaging (MRI) techniques are usually used for treatment evaluation. Surgery as well as chemoradiotherapy induce false positive results with changes in the affected area, including fibrosis and necrosis. These benign treatment-induced changes must be distinguished from true residual or recurrent tumors on imaging to prevent discontinuation or unfair initiation of therapy.

Head and neck cancer includes a broad group of common tumors that are often aggressive in their biological behavior. In addition, patients with head and neck cancer often develop a secondary primary tumor. These tumors occur at an annual rate of 3%-7% and 50%-75% of new cancers such as occur in the upper aerodigestive tract or lung.

Neck masses can be a confusing and challenging situation, especially in primary care. The differential diagnosis is very broad, even for experienced doctors. A solid understanding of the anatomy, etiology and clinical presentation of neck masses can quickly establish a diagnosis, reduce unnecessary laboratory tests, and increase patient satisfaction by reducing patient fear and anxiety.



Patients with malignancy have a poor quality of life, especially when faced with the late stages. Early detection and treatment of head and neck cancer can improve quality of life and better prognosis. Occult metastases may occur in about 10-30% of head and neck cancers. Occult metastases should be detected as early as possible for a better prognosis.⁴

The most important diagnostic step is a physical examination of the head and neck. Visualization and palpation are the most important components of the physical examination. This helps determine the location of the mass according to the area of lymphatic drainage, the size of the lesion and its relationship to surrounding structures (fixed or unfixed), the consistency of the mass, and throbbing (throbbing) or bruit. The physician should not focus on the neck mass and neglect to perform a thorough evaluation of the head and neck examination. The upper aerodigestive tract should be examined thoroughly, either by mirror or endoscope. Pulsating neck masses, bruits or thrills, ultrasonography may be performed to differentiate degenerative vascular problems (eg, aneurysms) from neoplastic conditions (eg, glomus and carotid tumors). Ultrasound can also help to differentiate solid and cystic masses, or congenital bronchial and thyroglossal cysts from solid, neurogenic, and ectopic lymph nodes. CT scan and MRI: differentiate cysts from solid lesions, locate masses inside or outside the gland, explain anatomic relationships.

CASE REPORT

A 66-year-old man comes to the Oncology Polyclinic with the chief complaint of swelling in the neck that occurs every day. The lump feels enlarged for more than 6 months. The patient claimed to have no pain but the patient complained of slight discomfort when swallowing and chewing. The patient admitted that this was the first time he had consulted and treated the disease in his neck. The patient had no history of smoking. There was no history of diabetes mellitus and tuberculosis in the patient.

On physical examination, blood pressure was 110/80 mmHg, respiratory rate was 22 times per minute, oxygen saturation was 98% with oxygen 2

liters per minute using a nasal cannula, and axillary temperature was 37.0°C. Other physical examinations were within normal limits. On laboratory examination, there was a decrease in hemoglobin, a decrease in leukocytes, a decrease in MCV, an increase in neutrophils, a decrease in lymphocytes, a decrease in urea, and an increase in SGOT.

On MRI examination, the first lesion was found: a large soft tissue mass in the left colli area, extending to the left parotid-left submandibular, left pterveoid muscle, left maxillary sinus, infiltration of the left ptic chiasm into the left retroorbital infiltration of the medial-lateral rectus muscle, superior oblique inferior medial lateral, left optic nerve, pushes the left bulbus oculi anteromedially. The second lesion was a strong homogenous contrast enhancement lesion in the left sphenoid wing area measuring about 3 × 4 cm.

The sulci and gyri appear normal, the ventricular and cystic systems appear fine. No midline deviation of the structure was seen. The pons and cerebellum appear fine. MR Angiography: Circulus Willis appeared patent, no aneurysm or vascular maltormation was seen. Conclusions MRI: The first lesion may still be an STT colli with extension to the left submandibular, left pterygoid muscle, left maxillary sinus, left optic chiasm infiltration, left CPA, left retroorbital. The second lesion may still have a left sphenoid meningioma .

DISCUSSION

The definition of a neck tumor is an enlargement, swelling or abnormal growth between the base of the skull and the clavicle. Neck masses in adult patients should be considered malignant until proven otherwise. Abnormalities of the head and neck may develop symptoms of a neck mass. Surgical excision was performed except for some inflammatory masses, for diagnostic purposes. When signs of inflammation are associated with the mass, antibiotic management with observation for up to 2 weeks can be performed.

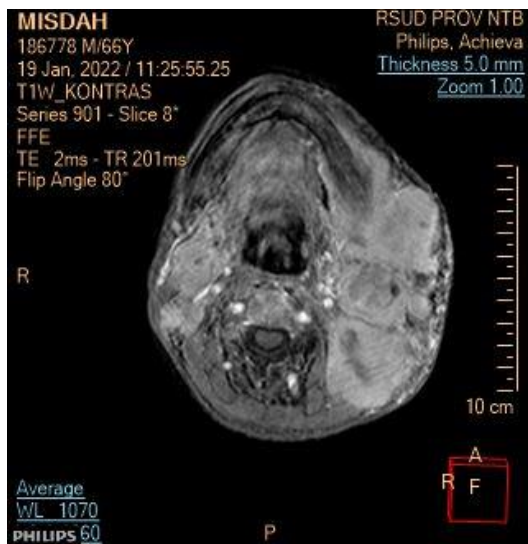
Primary tumors of the neck are rare, but should be considered in the differential diagnosis of any neck



mass to allow for optimal evaluation and management. The primary diagnosis often requires surgical resection, which may require wide resection with well-defined margins and neck dissection. This patient underwent an MRI examination with the impression that the first lesion may still be an STT colli with extension to the left submandibular, left pterygoid muscle, left maxillary sinus, left optic chiasm infiltration, left CPA, left retroorbital. The second lesion may still have a left sphenoid wing meningioma swat. (Image 1).

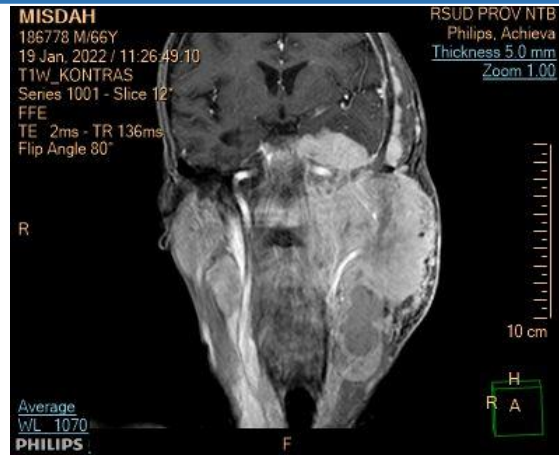
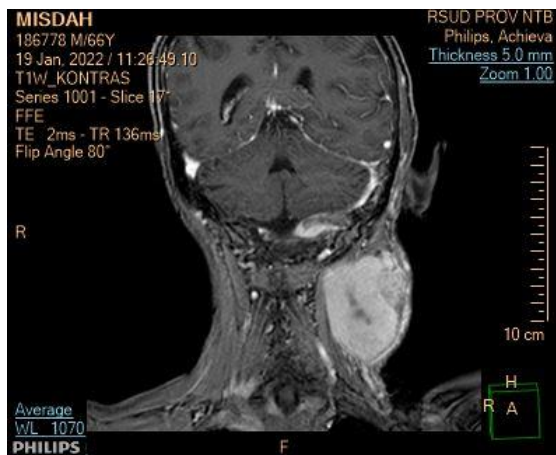
Image 1. MRI Image



Apart from MRI, other examinations can also be performed, such as ultrasound used to differentiate solid from cystic mass; very useful in congenital cysts, can also be useful for vascular lesions and tumor staging. Neck masses in patients with known primary tumors of the head and neck should be treated according to individual tumor principles. In general, when lymph node metastases occur, lymphadenectomy should be performed concurrently with removal of the primary tumor. If the primary tumor is not located in the head or neck, an excisional biopsy of the neck mass is performed to confirm the diagnosis and staging, further management depends on the primary tumor.^{5,6}

In addition, the differential diagnosis of this colli tumor can be neurofibromatosis type I and meningioma. Neurofibroma is a benign tumor of the nerve sheath, solitary neck mass or multiple tumor nodules. Neurofibromas are associated with von Recklinghausen's autosomal dominant disease. In contrast to schwannomas, neurofibromas are unencapsulated and histologically exhibit interwoven bundles of spindle cells. Like schwannomas, solitary neurofibromas undergo malignant transformation and are best treated by surgical resection. Surgery for neurofibromatosis is usually reserved for those lesions that are painful, those that can cause pressure around the area of a large size, or



those that are malignant. Neurofibromatosis type 1 (NF1) is a genetic condition that causes tumors to grow along nerves. Tumors are usually noncancerous (benign) but can cause a variety of symptoms. Neurofibromatosis type 2 (NF2) is much more common than NF1. Meningiomas can also be a differential diagnosis because meningiomas are extra-axial tumors and are the most common meningeal tumors. They are non-gliar neoplasms originating from the meningocytes or arachnoid guard cells of the meninges and located anywhere where the meninges are found, and in some places where only resting cells are thought to be present. For other examinations, FNAB may be performed before endoscopy but after a thorough head and neck examination. A pathologist is required for accurate FNAB results. FNAB has become the standard in making diagnostic and management decisions on neck masses. 7-9

FNAB is also used in patients with malignancy to confirm metastases required for tumor staging and treatment planning, in patients with primary neck tumors to initiate nonsurgical therapy, and in patients with unknown neck masses. FNAB can usually differentiate between cystic and inflammatory lesions, benign and malignant tumor lesions, lymphoma and carcinoma.10-11

CONCLUSIONS

We reported a 66-year-old male patient was suspected of having colli dd meningioma tumor. Although 90% of all patients with colli can be diagnosed on conventional clinical and radiological basis, a biopsy is mandatory for histological confirmation and treatment planning.

References

1. Lalwani A. CURRENT Diagnosis & Treatment Otolaryngology--Head and Neck Surgery, Third Edition.Edisi.: Mcgraw-hill; 2011.
2. Stewart MG, Selesnick SH. Differential Diagnosis in Otolaryngology: Head and Neck Surgery.Edisi.: Thieme; 2011.
3. Johnson JT, Rosen CA, Bailey BJ. Bailey's Head and Neck Surgery--otolaryngology.Edisi ke 5. Wolters Kluwer

- Health/Lippincott Williams & Wilkins; 2014.
4. Nakamura Y, Otsuka F. Sentinel Lymph Node Biopsy for Melanoma and Surgical Approach to Lymph Node Metastasis.Edisi.; 2013.
5. Nooij RP, Hof JJ, van Laar PJ, van der Hoorn A. Functional MRI for Treatment Evaluation in Patients with Head and Neck Squamous Cell Carcinoma: A Review of the Literature from a Radiologist Perspective. *Curr Radiol Rep.* 2018;6(1):2. doi:10.1007/s40134-018-0262-z
6. van der Hoorn A, van Laar PJ, Holtman GA, Westerlaan HE. Diagnostic accuracy of magnetic resonance imaging techniques for treatment response evaluation in patients with head and neck tumors, a systematic review and meta-analysis. *PLoS One.* 2017;12(5):e0177986. Published 2017 May 24. doi:10.1371/journal.pone.0177986
7. Wahid KA, He R, McDonald BA, et al. Intensity standardization methods in magnetic resonance imaging of head and neck cancer. *Phys Imaging Radiat Oncol.* 2021;20:88-93. Published 2021 Nov 20. doi:10.1016/j.phro.2021.11.001
8. Ren J, Eriksen JG, Nijkamp J, Korreman SS. Comparing different CT, PET and MRI multi-modality image combinations for deep learning-based head and neck tumor segmentation. *Acta Oncol.* 2021 Nov;60(11):1399-1406. doi: 10.1080/0284186X.2021.1949034. Epub 2021 Jul 15. PMID: 34264157.
9. Mignelli J, Tollefson LJ, Stefanowicz E. Conservative management of neck and thoracic pain in an adult with neurofibromatosis-1. *J Can Chiropr Assoc.* 2021;65(1):121-126.
10. Legius E, Messiaen L, Wolkenstein P, et al. Revised diagnostic criteria for neurofibromatosis type 1 and Legius syndrome: an international consensus recommendation. *Genet Med.* 2021;23(8):1506-1513. doi:10.1038/s41436-021-01170-5
11. Gaillard, F. Meningioma. Reference article, Radiopaedia.org. (accessed on 28 Jan 2022) <https://doi.org/10.53347/rID-1659>