

Necrotizing Enterocolitis: Pathophysiology, Diagnosis and Treatment

Yumna Iftinan Khalda^{1*}, Ranti Filarma Negara Purnama¹, Lale Srigading Udayanti¹, Izza Ahmad Muharis¹, Jannatul Cahya Admiyanti¹, Yusra Pintaningrum²

¹ Faculty of Medicine, University of Mataram, Mataram, Indonesia

² Department of Cardiology, Faculty of Medicine, University of Mataram, Mataram, Indonesia

DOI: 10.29303/lmj.v2i1.2390

Article Info

Received : March 2023

Revised : April 2023

Accepted : May 2023

Abstract: Necrotizing enterocolitis (NEC) is an inflammation of the intestine and is more common in premature infants. The prevalence of NEC increased in children with birth weight <1500 grams and gestational age <28 weeks. The pathophysiology of NEC is not fully understood, but the mechanisms that may be associated including intraluminal bacterial invasion through toll-like receptor 4 (TLR-4) and activating inflammatory reactions. In addition, impaired intestinal microcirculation and dysbiosis are also said to be associated with the disease pathogenesis. Diagnosis and staging of the disease is done using *Bell's Modified Staging Criteria*, consisting of mild, moderate and severe phases. Due to the poor prognosis of NEC, adequate and quick management are required.

Keywords: necrotizing enterocolitis; pathophysiology; management; diagnosis; prognosis

Introduction

Necrotizing enterocolitis (NEC) is an inflammatory condition of the infant gut that causes high morbidity and mortality rates, especially in extremely preterm infants (less than 28 weeks) with low birth weight (Bazacliu & Neu, 2019). It is often associated with sepsis and leads to complications such as perforation, peritonitis, and even death. The etiology of NEC is unclear (Curtis & Terrin, 2013). The incidence of the disease is found to be 1-3 cases per 1000 live births. NEC is more common in extremely preterm infants (under 28 weeks gestation), as they still have immature intestines (Lee & Polin, 2003). NEC conditions that do not receive immediate treatment can increase the risk of short bowel syndrome (SBS) in premature infants (Macdonald & Green, 2018). The pathogenesis of this disease is unknown, as it involves a multifactorial process. Risk factors such as prematurity, infection, changes in the gut microbiota, and inadequate gut barrier function may ultimately lead to the activation of the inflammatory cascade (Gomella et al., 2020; Hartini et al., 2013; Neu & Walker, 2011).

Definition and Epidemiology

Email: yumnaiftinan@gmail.com (*Corresponding Author)

Necrotizing enterocolitis is an inflammation of the intestine that occurs as a result of immature or impaired development of the gastrointestinal tract. NEC is characterized by an inflammatory condition and often bacterial invasion (Alganabi et al., 2019). This condition is most commonly seen in premature infants (Kelleher et al., 2021). NEC is found in 4-10% of infants with a birth weight of less than 1500 grams, with the highest incidence in preterm infants. Approximately 10% of cases of NEC in full-term infants are accompanied by pre-existing medical conditions (Gomella et al., 2020).

Pathophysiology

The pathophysiology of necrotizing enterocolitis is multifactorial. One of the pathophysiology associated with NEC is that intraluminal bacteria invade the intestinal epithelium through its villous ends. Endotoxins from these bacteria bind to toll-like receptor 4 (TLR-4) on intestinal epithelial cells and activate pathogen-associated molecular pattern receptors (PAMP receptors), causing intestinal barrier damage and enterocyte apoptosis (Gomella et al., 2020). This further activates an inflammatory response in the lamina propria mediated by tumor necrosis factor-alpha (TNF-

c), interleukin-1 β (IL-1 β), and other inflammatory cytokines. Vasoactive substances associated with NEC are also released into the gut, such as platelet-activating factor (PAF), endothelin-I (ET-I), and nitric oxide (NO). The inflammatory response also activates the complement and coagulation systems. In this case, leukocytes and platelets adhere to the endothelium to prevent blood flow in the microvascular of the small intestines and cause damage to the tissue (Alganabi et al., 2019). Risk factors associated with NEC include prematurity, gut dysbiosis (impaired gut microbes), impaired mucosal defense mechanisms, altered immune response, infant formula feeding, medications such as antibiotics and H2-blockers, genetic predisposition, red blood cell transfusions and maternal smoking during pregnancy (Gomella et al., 2020; Neu & Walker, 2011).

Preterm infants have increased TLR-4 expression in the intestinal epithelium. TLR-4 plays an important role in the activation of innate immunity by recognizing specific patterns of microbial components. TLR-4 is activated by lipopolysaccharides on gut lumen microbes, resulting in damage to the gut lumen. This allows luminal bacterial translocation, vasoconstriction, intestinal ischemia, and the occurrence of NEC (Bazacliu & Neu, 2019). In addition to TLR-4 expression, impaired intestinal microcirculation is also one of the pathophysiologies that play a role in NEC. Impaired microcirculation leads to poor blood flow, which will play a role in facilitating the inflammatory cascade and ultimately lead to the deterioration of the disease process (Bazacliu & Neu, 2019).

Dysbiosis also plays a role in the pathophysiology of NEC. Dysbiosis is a disturbance in the development and homeostasis of the gut microbiota. Preterm infants who have been diagnosed with NEC have an increase in *Proteobacteria* (Gammaproteobacteria class or Enterobacteriaceae family). *Proteobacteria* will be recognized by the immune system through TLR-4 and play a role in intestinal inflammation which can lead to the development of NEC disease in infants (Bazacliu & Neu, 2019; Pammi et al., 2017).

Oxidative stress and reactive species such as superoxide are also involved in the pathophysiology of NEC. Oxidative stress is a condition of imbalance in the production of oxidative reactive species with antioxidant defense. Preterm infants have poor antioxidant defense because the increase in antioxidant capacity in infants occurs at the end of pregnancy (Nair & Lakshminrushimha, 2019). Oxidative stress can disrupt the microvascular balance in the intestine by increasing the production of vascular regulators such as nitric oxide, which in turn plays a role in the pathogenic cascade of disease (Choi, 2014).

Stress modulated by inducible nitric oxide synthase (iNOS) leads to high concentrations of nitric

oxide (NO) in the intestinal microcirculation. NO further suppresses intestinal oxygen consumption (Nowicki et al., 2005). NO also reacts with other superoxides to produce peroxynitrite, one of the oxidants that cause ischemia. This ischemic condition in the intestine will then cause cellular and tissue damage (Nair & Lakshminrushimha, 2019).

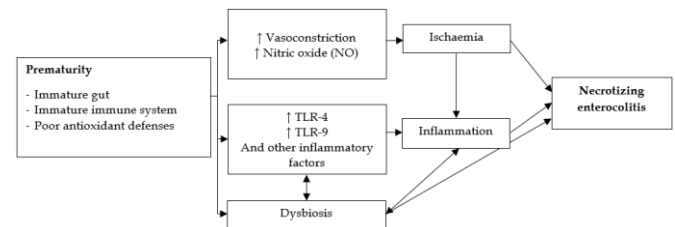


Figure 1. Pathophysiology of Necrotizing Enterocolitis

Diagnosis

Initial clinical manifestations in patients with necrotizing enterocolitis have no specific symptoms, include temperature instability, apnea, bradycardia, hypotension, increased gastric residue, emesis, redness, abdominal tenderness and distension, loss of bowel noise, mass in the right lower quadrant, and blood stained fecal. Laboratory investigations revealed thrombocytopenia, neutropenia, elevated *C-reactive protein*, metabolic acidosis, electrolyte imbalance, and coagulopathy (Taufik & Lestari, 2021).

The diagnosis and staging of necrotizing enterocolitis are based on *Bell's Modified Staging Criteria*, which has three clinical stages: mild, moderate, and severe. (1) Mild stage (*Bell's stage I*) has clinical manifestations such as temperature instability, bradycardia, mild abdominal distension, and a small amount of blood in the stool. (2) Moderate stage (*Bell's stage II*) has more severe clinical manifestations than the previous stage. Symptoms may include abdominal tenderness, thrombocytopenia, and metabolic acidosis; radiology examination may reveal intestinal pneumatosis and/or portal vein gas. (3) Severe stage (*Bell's stage III*), at this stage, the clinical manifestations are severe due to intestinal perforation, which requires surgery. Other symptoms include pneumoperitoneum, hypotension, signs of peritonitis, and severe metabolic acidosis (Meister et al., 2020).

The time-standard examination to determine the diagnosis of necrotizing enterocolitis is abdominal radiology. The examination will reveal intestinal pneumatosis, portal vein air, or pneumoperitoneum (D'Angelo et al., 2018). As a result of anaerobic bacterial metabolism, air will be found in the intestinal submucosal layer, which is called intestinal pneumatosis. Then, some of the indications for surgery

are also found due to the presence of pneumoperitoneum (Taufik & Lestari, 2021).

The supporting examination that can be done for this disease is abdominal ultrasound. In this examination, there is no radiation exposure, and neonates with preterm birth have thin abdominal walls, so this examination can be used. In addition, most of the intestine is fluid-filled, and it is possible to perform a more detailed visualization of the intestinal wall. Other results that can be found in abdominal ultrasound are size and shape, wall thickness, degree of dilatation, pneumatosis, portal vein air, presence of intra-abdominal free fluid, and indications of intestinal perforation (D'Angelo et al., 2018; Taufik & Lestari, 2021). Abdominal ultrasound can be performed in cases that show insignificant clinical symptoms or radiologic results and can be performed to evaluate cases of infants with NEC who do not respond to therapy (Gomella et al., 2020).

Some diseases have similar clinical manifestations to NEC, such as spontaneous intestinal perforation (SIP). NEC and SIP can both be characterized by abdominal distension and free air in the abdominal cavity. In SIP, the disease occurs earlier than in NEC. In SIP, there is also thinning of the intestinal muscularis propria and intestinal perforation without inflammation or necrosis in the area around the perforation. Besides SIP, other conditions that show clinical manifestations similar to NEC are sepsis and viral enterocolitis (Neu, 2020). Sepsis in neonate cases has clinical manifestations similar to NEC stages I and II, such as vomiting, abdominal distension, and no bowel noise. What can differentiate the two is the abdominal radiology examination. In viral enterocolitis, early symptoms may include lymphocytes which are rarely found in cases of NEC (Taufik & Lestari, 2021).

Treatment

The first line of management in NEC patients is conservative management, which involves stopping all enteral feedings and maintaining *nil per os* (NPO). A nasogastric tube is placed to decompress the dilated bowel, while intravenous antibiotics are started with a broad spectrum.

Total parenteral nutrition (TPN) consists of carbohydrates, amino acids, fats, electrolytes, minerals, and vitamins, administered intravenously to allow the bowel to rest. Parenteral nutrition should be started with adequate protein, about 3,5-4 g/kg/day, to maintain nitrogen balance, increase infant weight, and repair tissue damage (Ou et al., 2020). Preterm infants receiving total parenteral nutrition should be monitored regularly. Monitoring on the first day should be more frequent, and when the infant's condition is more stable, a complete blood test should be done once a week to

ensure adequate nutrition and no further complications (Türkyılmaz et al., 2018).

The antibiotic regimens that can be given such as ampicillin, gentamicin, clindamycin, or metronidazole. If conservative therapy is effective, enteral feeding can be continued after signs of infection disappear in the infant, usually taking up to a week in some cases (Ginglen & Butki, 2022).

Surgical management can be performed if the patient's condition worsens, such as pneumoperitoneum, abdominal mass with persistent obstruction, and intestinal proliferation that does not respond to medical therapy. Laparotomy is a surgery that removes necrotic or perforated parts of the intestine in an attempt to preserve the intestine and ileocecal valve (Ginglen & Butki, 2022). Some laparotomy procedures depend on the neonate's condition and the extent of the affected bowel, such as focal, multifocal, and total. In stable patients with focal and multifocal bowel damage, the main points are resection and primary anastomosis (Taufik & Lestari, 2021). Ostomy, a surgical procedure to create an opening in the abdominal wall, is indicated in extreme conditions of the infant or significant peritonitis (Ginglen & Butki, 2022).

In patients with >75% bowel damage, the alternatives are jejunostomy and *clip and drop technique*. Jejunostomy may be chosen if bowel resection causes significant bleeding or loss of the majority of bowel length in an attempt to avoid extensive bowel resection and stromal complications, whereas clip and drop technique is indicated in extensive bowel resection and stoma-induced complications (Taufik & Lestari, 2021). After surgery, the infant should receive intravenous antibiotics and total parenteral nutrition for at least 2 weeks as well as monitoring for correction of electrolyte imbalance in anemia, and ventilatory support should be provided if needed (Ginglen & Butki, 2022).

Prognosis

According to the National Institute of Child Health and Human Development (NICHD), only some infants survive after surgery. Mortality rates range from 10-50%, increasing with shorter gestational age and surgical intervention. NEC is associated with a risk of impaired growth and impaired nervous system development. Among infants with NEC, 56.7% have neurodevelopmental disorders, such as cerebral palsy, blindness, and deafness (Ginglen & Butki, 2022; Gomella et al., 2020).

Conclusion

Necrotizing enterocolitis is an inflammatory bowel disease that occurs more commonly in premature infants. The pathophysiology of the disease is not clearly

known, as it is multifactorial. Some of the mechanisms associated with the disease are inflammatory reaction, intestinal microcirculation disorder, and dysbiosis. Several risk factors also play an important role in the disease process, such as prematurity, formula feeding, medications such as antibiotics or H2-blockers, genetics, red blood cell transfusions, and a history of smoking in pregnant women. The prognosis of the disease is poor, the mortality rate due to NEC ranges from 10-50% of cases, requiring adequate management in the form of conservative management, such as NPO, bowel decompression, and antibiotic administration.

References

- Alganabi, M., Lee, C., Bindi, E., Li, B., & Pierro, A. (2019). Recent advances in understanding necrotizing enterocolitis [version 1; referees: 2 approved]. *F1000Research*, 8(0), 1-8. <https://doi.org/10.12688/f1000research.17228.1>
- Bazacliu, C., & Neu, J. (2019). Pathophysiology of Necrotizing Enterocolitis: An Update. *Current Pediatric Reviews*, 15(2), 68-87. <https://doi.org/10.2174/1573396314666181102123030>
- Choi, Y. Y. (2014). Necrotizing enterocolitis in newborns: Update in pathophysiology and newly emerging therapeutic strategies. *Korean Journal of Pediatrics*, 57(12), 505-513. <https://doi.org/10.3345/kjp.2014.57.12.505>
- Curtis, M. De, & Terrin, G. (2013). Necrotizing enterocolitis (NEC): what's going on. *Journal of Pediatric and Neonatal Individualized ...*, 2(2), 1-7. <https://doi.org/10.7363/020218>
- D'Angelo, G., Impellizzeri, P., Marseglia, L., Montalto, A. S., Russo, T., Salamone, I., Falsaperla, R., Corsello, G., Romeo, C., & Gitto, E. (2018). Current status of laboratory and imaging diagnosis of neonatal necrotizing enterocolitis. *Italian Journal of Pediatrics*, 44(1), 1-6. <https://doi.org/10.1186/s13052-018-0528-3>
- Ginglen, J. G., & Butki, N. (2022). *Necrotizing Enterocolitis*.
- Gomella, T. L., Eyal, F. G., & Mohammed, F. B. (2020). Gomella's Neonatology. In *Mc-Graw Hill Education* (8th ed., Vol. 1999, Issue December).
- Hartini, K., Artana, D., & Putra, J. (2013). KARAKTERISTIK ENTEROKOLITIS NEKROTIKANS PADA NEONATUS YANG DIRAWAT DI RSUP SANGLAH. *Jurnal Ilmiah Kedokteran*, 44(4), 19-24.
- Kelleher, S. T., McMahan, C. J., & James, A. (2021). Necrotizing Enterocolitis in Children with Congenital Heart Disease: A Literature Review. *Pediatric Cardiology*, 42(8), 1688-1699. <https://doi.org/10.1007/s00246-021-02691-1>
- Lee, J. S., & Polin, R. A. (2003). Treatment and prevention of necrotizing enterocolitis. *Seminars in Neonatology*, 8(6), 449-459. [https://doi.org/10.1016/S1084-2756\(03\)00123-4](https://doi.org/10.1016/S1084-2756(03)00123-4)
- Macdonald, A., & Green, J. (2018). Necrotising enterocolitis and neonatal sepsis: A literature review. *Journal of Neonatal Nursing*, 24(2), 80-85. <https://doi.org/10.1016/j.jnn.2017.08.001>
- Meister, A. L., Doheny, K. K., & Travagli, R. A. (2020). Necrotizing enterocolitis: It's not all in the gut. *Experimental Biology and Medicine*, 245(2), 85-95. <https://doi.org/10.1177/1535370219891971>
- Nair, J., & Lakshminrushimha, S. (2019). Role of NO and other vascular mediators in the etiopathogenesis of necrotizing enterocolitis. *Frontiers in Bioscience*, 11, 9-28.
- Neu, J. (2020). Necrotizing Enterocolitis: The Future. *Neonatology*, 117(2), 240-244. <https://doi.org/10.1159/000506866>
- Neu, J., & Walker, W. A. (2011). Necrotizing Enterocolitis. *National Institutes of Health*, 364(3), 255-264. <https://doi.org/10.1056/NEJMra1005408>
- Nowicki, P. T., Dunaway, D. J., Nankervis, C. A., Giannone, P. J., Reber, K. M., Hammond, S. B., Besner, G. E., & Caniano, D. A. (2005). Endothelin-1 in human intestine resected for necrotizing enterocolitis. *Journal of Pediatrics*, 146(6), 805-810. <https://doi.org/10.1016/j.jpeds.2005.01.046>
- Ou, J., Courtney, C. M., Steinberger, A. E., Tecos, M. E., & Warner, B. W. (2020). Nutrition in necrotizing enterocolitis and following intestinal resection. *Nutrients*, 12(2), 1-16. <https://doi.org/10.3390/nu12020520>
- Pammi, M., Cope, J., Tarr, P. I., Warner, B. B., Morrow, A. L., Mai, V., Gregory, K. E., Simon Kroll, J., McMurtry, V., Ferris, M. J., Engstrand, L., Lilja, H. E., Hollister, E. B., Versalovic, J., & Neu, J. (2017). Intestinal dysbiosis in preterm infants preceding necrotizing enterocolitis: A systematic review and meta-analysis. *Microbiome*, 5(1), 1-15. <https://doi.org/10.1186/s40168-017-0248-8>
- Taufik, M. L., & Lestari, D. (2021). Diagnosis dan Tatalaksana Enterokolitis Nekrotikans. *Cermin Dunia Kedokteran*, 48(4), 225-230. <http://www.cdkjournal.com/index.php/CDK/article/view/1366>
- Türkyılmaz, C., Bilgen, H., & Kültürsay, N. (2018). Turkish neonatal society guideline on the parenteral nutrition in preterm infants. *Türk Pediatri Arsivi*, 53, S119-S127. <https://doi.org/10.5152/TurkPediatriArs.2018.01812>